

Research Compact

Tags

Octenilin, Wound, Scar

Title

An intra-individual surgical wound comparison shows that octenidine-based hydrogel wound dressing ameliorates scar appearance following abdominoplasty

Authors

Matiasek J, Kienzl P., Unger L.W., Grill C., Koller R., Turk B.R.

Source

2018, International Wound Journal, <https://doi.org/10.1111/iwj.12944>

Aim of the study

The formation of hypertrophic scars after surgical procedures is associated with higher pain, poorer cosmetic outcome, and overall higher postoperative care costs for patients. The cosmetic appearance of scars is one of the most important patient-reported outcome of wound healing. The influence of an octenidine-based wound gel on scar appearance on patients who have undergone abdominoplasty, mastectomy with transverse rectus abdominis muscle (TRAM) flap reconstruction was investigated.

Methods

The study was randomised, observer blinded and intra-patient controlled regarding wound healing and scar formation. Each patient received both a standard wound dressing for one side, and octenidine-based wound gel with a transparent film dressing for the other side. The Vancouver Scar Scale (VSS - a validated scar assessment scale) was employed after 3, 6 and 12 months post surgery. Skin elasticity, transepidermal water loss and moisture levels in the stratum corneum were also determined.

Results

In 12 patients, hypertrophic scars appeared 12 months after surgery on the control side, but only 4 on the OCT wound gel side. The pain sensation determined by the Visual Analog Scale was less pronounced on the OCT wound gel side than on the control side at all time points. Vancouver Scar Scale scores showed significantly better results on the gel side than the control side at 3, 6, and 12 months (Figure 1). Skin elasticity, transepidermal water loss and moisture levels each also showed better values on the gel side.

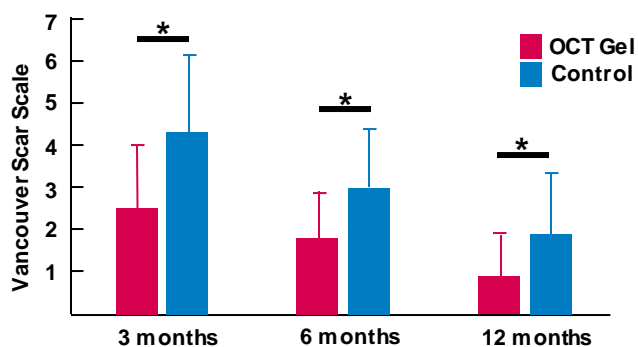


Figure 1: Vancouver Scar Scale result. Vancouver Scar Scale score at 3, 6 and 12 months.
*significant difference $p < 0,05$.

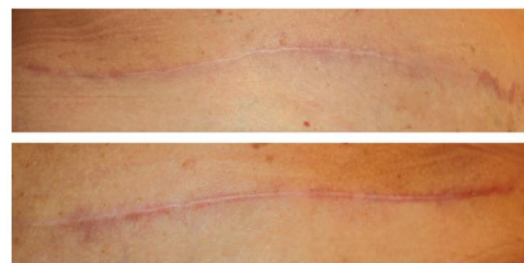


Figure 2: Example of a scar 12 months after surgery. The side treated with OCT wound gel is shown above. The control side at the bottom.

Conclusion

The use of an octenidine-containing wound gel provides a significantly improved scar appearance compared to conventional wound care.